

# Influence of Fasting and Feed Constituents Size Variation on Broiler Performance and Intestinal Demonstrations

Asad Ali Khaskheli<sup>1,\*</sup> and Li Chou<sup>2</sup>

<sup>1</sup>Centre for Nutrition and Food Sciences, Queensland Alliance for Agriculture and Food Innovation, The University of Queensland,

Brisbane Qld 4072 Australia; <sup>2</sup>Kasetsart University, Thailand

Received: July 17, 2020; Revised: September 3, 2020; Accepted: September 8, 2020

## Abstract

Investigation was performed to elucidate the effects of fasting and feed constituents' size variation on broilers performance and GIT demonstrations. Experiment was performed on 90 newly hatched chicks by dividing them into 3 treatment groups including T1, T2 and T3. Chicks in group T1 were fasted for 48 hours, T2 were fed a coarsely ground diet and T3 were finely ground mash diet. Results showed significant difference for residual egg yolk weight ( $2.54 \pm 0.29^a$ ) and final body weight ( $50.1 \pm 0.3^b$ ) in group T1; however, concerning weight of proventriculus + gizzard significant difference occurred in the group T2 ( $8.20 \pm 0.08^a$ ). Chicks in group T1 possessed significantly higher weight of pancreas ( $0.32 \pm 0.00^b$ ), jejunum ( $2.28 \pm 0.05^b$ ) and ileum ( $1.98 \pm 0.14^b$ ), while length of duodenum appeared higher in group T2 ( $25.92 \pm 0.51^a$ ) followed by T3 ( $20.32 \pm 0.77^b$ ) and T1 ( $18.24 \pm 0.29^c$ ). Length of jejunum ( $41.44 \pm 0.82^a$ ) and ileum ( $40.22 \pm 0.93^a$ ) was significantly different in group T2. Duodenum villi height, cell area and muscularis externa thickness were significantly different in the group T1; however, body weight gain, diet intake and feed conversion efficiency showed significant difference in the group T2. Study concludes that post hatch fasting negatively affects the growth performance, gross and histological structures of digestive organs in broilers.

**Keywords:** Broilers, Intestinal morphology, Villi, Post hatching

## 1. Introduction

In broiler industry, baby chicks are not given instantaneous water and feed. Hatched birds are only transferred from the incubators, when majority of chicks have been hatched, and it takes 12 - 24 hours (Wang and Peng, 2008). Furthermore, hatchery operation procedures like vaccination, sexing, packaging and transportation are also key factors responsible for fasting of chicks (Batal and Parsons, 2002). Although, chicks start their growth and search for feed immediately after hatching, but due to late feed supply, chicks suffer starvation of 1 or 1.5 day and that results sufficient loss of body weight, dehydration, energy depletion and slow immune and GIT system development (Boersma *et al.*, 2003). In such cases, inherited nutrients from yolk sac are only liveliness source before appropriate diet utilization. The GIT develops quickly compared to other organs following hatching and act as an important part for chicks' growth during early stage (Henderson *et al.*, 2003). The GIT serves as vital part for nutrients digestion and assimilation in the body. Intestinal development can only be assessed through the measurement of crypts, site of new intestinal cells formation, villus height and surface area (Franco *et al.*, 2006). Recent past studies have reported that GIT development depends on fed, alterations in villus shape and the type of species. It may be severely impaired by delayed feeding, because fasting depresses the expression

of transcription factors *cdxA* and *cdxB*, which plays major role in the intestinal development and maintenance (Geyra *et al.*, 2001).

Although growth rate of broiler chicks is much faster, but it is influenced by intestinal development which undergoes dramatic changes during first few days of chicks' life to accommodate the rapid conversion and utilization of external nutrients (Krás *et al.*, 2013). These dramatic changes include rapid increase in mass, villi number, villi length, enterocytes number, proliferating cells and depth of crypts (Friedman *et al.*, 2003). Compared to carcass, weight of small intestines increases more quickly, and it peaks on 6 to 10<sup>th</sup> day. The length and weight of intestine have direct correlation with nutrients digestion and absorption which in turn influence the weight gain of chicks (Mateos *et al.*, 2012). Further, the type of strain and species of birds are also key variables to affect the weight and length of the small intestines (Hassouna, 2001). Gross and histological researches have reported that the duodenum, jejunum and ileum are three main parts which comprises the small intestine, while tunica serosa, tunica muscularis and tunica mucosa are 3 sheets which compose their wall (Rougière *et al.*, 2009). Inner mucosal layer is again divided into three sub-layers like laminae submucosa, muscularis mucosae and propria. Likewise, muscularis tunica is divided into two sub-layers like lamina longitudinalis and lamina subserosa. Tunica mucosa contains villi. These villi are actually hair like structures towards the lumen (Silva *et al.*, 2007).

\* Corresponding author e-mail: khaskheli@gmail.com, a.ali1@uqconnect.edu.au

Numerous microvilli are also found on surface that comprise the brush. Transportation as well as absorption of monosaccharides, fatty acids and amino acids is carried by enterocytes (Pourreza *et al.*, 2012). Furthermore, mucus producing cells and intraepithelial lymphocytes are also present besides the enterocytes. Mucus secreting cells are dispersed on epithelial lining, while lumen is roofed by microvilli. They produce mucin and glycoproteins for protection (Khambualai *et al.*, 2009). Depth of mucosa and villi height are key indicators, though are commonly used for evaluating the intestinal status of chickens and differential growth of epithelium (Incharoen and Maneechote, 2013). However, Jia *et al.* (2010) stated that the growth of villi depends on the feeding.

It is assumed that the use of whole grains or coarsely ground feed has significant influence on the gastrointestinal functions and health of chicks (Huang *et al.*, 2006). The presence of gizzard is a unique feature of the poultry birds which enables chicks to take up and digest coarse feed particles, thus it is less advantageous to grind the feed for achieving better digestion. Poultry birds prefer larger feed particles instead of smaller ones (Peron *et al.*, 2005), but the precondition is complete development of digestive system otherwise their performance will decrease. By reviewing past literature, it has been found that the influence of feed particle size variation on performance parameters has rarely been investigated in the broilers (Svihus *et al.*, 2010). Current study was thus planned in order to observe the influence of fasting and feed particle size variation on the growth performance and intestinal demonstrations in broiler chicks, especially during the starter period.

## 2. Materials and methods

Current research was performed at the Poultry Research Station, department of Animal Science, Kasetsart University, Thailand. All the experiments and procedures were carried by trained researcher under the guidelines verified by Animal Care and Use Committee (KU - AQ570503) of Kasetsart University. Experimental trial included a total of One Hundred newly hatched Ross 308 broiler chicks. From Hundred, total of 90 birds were allocated into 3 groups *viz.*, T1, T2 and T3 containing 30 chicks in each. Chicks in group T1 were fasted for 48 hours, T2 were fed a coarsely ground diet, while in group T3 were fed a finely ground mash diet. Chicks were individually examined and weighed. Though having uniform weights, they were tibia tagged and reared into 15 battery cages. After 48 hours, chicks were reweighed again and a total of 5 were slaughtered from every group for observing visceral organs. The GIT and concerned organs were collected for further study in the laboratory like gross and histological examinations. For gross examination, length, position, shape, size, width and weight of all visceral organs like residual yolk, liver, proventriculus, gizzard, pancreas, ceca, duodenum, jejunum and ileum were focused. However, for histological observation, small portions of all visceral organs were collected and fixed into the fixative solution. Specimen size ranged from 2 to 3 cm. Specimens were washed with Phosphate Buffered Saline (PBS) having molarity 0.1. Fixed samples were implanted in paraffin then cut into sections of 5  $\mu$ m size. Glass slides were cleaned, and transverse segments were

mounted on different glass slides. Staining was carried using hematoxylin as well as eosin. Last, slides were examined by microscope. Height and area of villi, area of cell, thickness of mucosa, muscularis externa of the intestinal parts were key variables to measure for intestinal morphology.

Moreover, chicks of each group were reared for further period of 14 days. Treatment groups remained same *viz.* T1, T2 and T3. Diet was given on ad libitum to the birds, while photoperiod was continuous lighting of 24hours. Temperature was adjusted to 32°C on day numbered first and then gradually reduced according to usual brooding practice. Data regarding different parameters like body weight, weight gain, feed intake and feed conversion efficiency was recorded.

### 2.1. Diet composition for chicks

For meeting the nutrients requirement of chicks, maize and soya meal-based diet was formulated (Table 1). Composed diet for different treatment groups contained same kinds of nutrients excepting particle size which was varying with treatment group. The coarse and finely ground mash diets were prepared by grinding the corn and soybean meal in the hammer mill to pass through 6 mm or 3 mm screen and their mixture were combined with other feed components.

**Table 1.** Diet composition of experimental birds

Ingredients	Dry matter basis (%)
Corn meal	40.00
Rice bran	15.00
Soybean meal	40.00
Palm oil	1.00
DL-Methionine	0.20
Dicalcium phosphate	2.00
Calcium carbonate	0.90
Sodium chloride	0.40
Premix	0.50
Chemical composition	
Crude protein	22.00
Ether extract	4.00
Crude fiber	4.00
Crude ash	6.00
Calcium	0.80
Available phosphorus	0.45
ME (kcal / kg)	3,000

### 2.2. Statistical Analysis

Results regarding all study parameters were analyzed by using software, Statistix version 8.1. The data was expressed in terms of means  $\pm$  SE. Means were compared by applying Duncan's multiple range test. Difference was considered significant at  $P < 0.05$ .

## 3. Results and Discussion

### 3.1. Intestinal demonstrations

Results regarding the different parameters like initial body weight (grams), final body weight (grams), weight of visceral organs (grams), weight of intestine (grams) and length of intestine (centimeters) in different treatment groups are shown in the Table 2. Results indicate that initial body weight was higher in the group T2 ( $40.9 \pm 0.3$ )

followed by T3 ( $40.7 \pm 0.5$ ) and T1 ( $39.7 \pm 0.4$ ) liver weight was higher in group T1 ( $3.54 \pm 0.06$ ) followed by T3 ( $3.50 \pm 0.12$ ) and T2 ( $3.32 \pm 0.13$ ), ceca weight was higher in group T3 ( $1.60 \pm 0.19$ ) followed by T1 ( $1.40 \pm 0.09$ ) and T2 ( $1.38 \pm 0.08$ ), while duodenum weight was found higher in group T2 ( $1.88 \pm 0.17$ ) followed by T3 ( $1.87 \pm 0.05$ ) and T1 ( $1.86 \pm 0.06$ ). Although means varied from one another, but statistically no significant ( $P > 0.05$ ) difference was found among all groups for initial body weight, ceca weight, liver weight and duodenum weight.

Results further indicate no significant ( $P > 0.05$ ) variation in the group T3 ( $62.8 \pm 0.7^a$ ) and T2 ( $63.8 \pm 0.5^a$ ), but the group T1 ( $50.1 \pm 0.3^b$ ) statistically differed from group T2 and T3 against final body weight. Regarding residual yolk weight, significant difference ( $P < 0.05$ ) was found in the group T1 ( $2.54 \pm 0.29^a$ ), while between group T3 ( $1.48 \pm 0.29^b$ ) and T2 ( $1.28 \pm 0.09^b$ ) no significant ( $P > 0.05$ ) change was noticed. Regarding weight of proventriculus + gizzard significant ( $P < 0.05$ ) difference occurred in the group T2 ( $8.20 \pm 0.08^a$ ) but among group T1 ( $7.10 \pm 0.24^b$ ) and T3 ( $7.10 \pm 0.16^b$ ) no significant ( $P > 0.05$ ) difference was observed.

**Table 2.** Growth rate, visceral organs weight, intestinal weight and intestinal length of chicks under the influence of fasting and feed particle size variation

Study parameters	Treatment groups		
	T1	T2	T3
<b>Growth rate (g / bird)</b>			
Initial body weight	$39.7 \pm 0.4$	$40.9 \pm 0.3$	$40.7 \pm 0.5$
Final body weight	$50.1 \pm 0.3^b$	$63.8 \pm 0.5^a$	$62.8 \pm 0.7^a$
<b>Visceral organ weight (g / 100 BW)</b>			
Residual Yolk	$2.54 \pm 0.29^a$	$1.28 \pm 0.09^b$	$1.48 \pm 0.29^b$
Liver	$3.54 \pm 0.06$	$3.32 \pm 0.13$	$3.50 \pm 0.12$
Proventriculus + gizzard	$7.10 \pm 0.24^b$	$8.20 \pm 0.08^a$	$7.10 \pm 0.16^b$
Pancreas	$0.32 \pm 0.00^b$	$0.44 \pm 0.02^a$	$0.44 \pm 0.02^a$
Ceca	$1.40 \pm 0.09$	$1.38 \pm 0.08$	$1.60 \pm 0.19$
<b>Intestinal weight (g / 100 BW)</b>			
Duodenum	$1.86 \pm 0.06$	$1.88 \pm 0.17$	$1.87 \pm 0.05$
Jejunum	$2.28 \pm 0.05^b$	$3.30 \pm 0.15^a$	$3.22 \pm 0.25^a$
Ileum	$1.98 \pm 0.14^b$	$2.64 \pm 0.09^a$	$2.90 \pm 0.21^a$
<b>Intestinal length (cm / 100 BW)</b>			
Duodenum	$18.24 \pm 0.29^c$	$25.92 \pm 0.51^a$	$20.32 \pm 0.77^b$
Jejunum	$34.00 \pm 1.41^b$	$41.44 \pm 0.82^a$	$36.30 \pm 0.95^b$
Ileum	$31.44 \pm 1.02^b$	$40.22 \pm 0.93^a$	$33.24 \pm 0.17^b$

<sup>a-c</sup>Means within each row differ with letter designations ( $P < 0.05$ )

**Table 3.** Growth performance of broiler chicks under the influence of fasting and feed particle size (Mean  $\pm$  SE)

Study parameters	Treatment groups		
	T1	T2	T3
Body weight (g / bird)	$399.7 \pm 4.8^b$	$432.2 \pm 3.0^a$	$403.3 \pm 6.7^b$
Weight gain (g / bird)	$360.2 \pm 5.1^b$	$391.5 \pm 2.9^a$	$363.7 \pm 7.1^b$
Feed intake (g / bird)	$566.7 \pm 11.4^a$	$594.8 \pm 7.5^a$	$511.7 \pm 18.3^b$
Feed efficiency	$0.67 \pm 0.02$	$0.69 \pm 0.02$	$0.73 \pm 0.03$

<sup>a-b</sup>Means within each row differ with letter designations ( $P < 0.05$ )

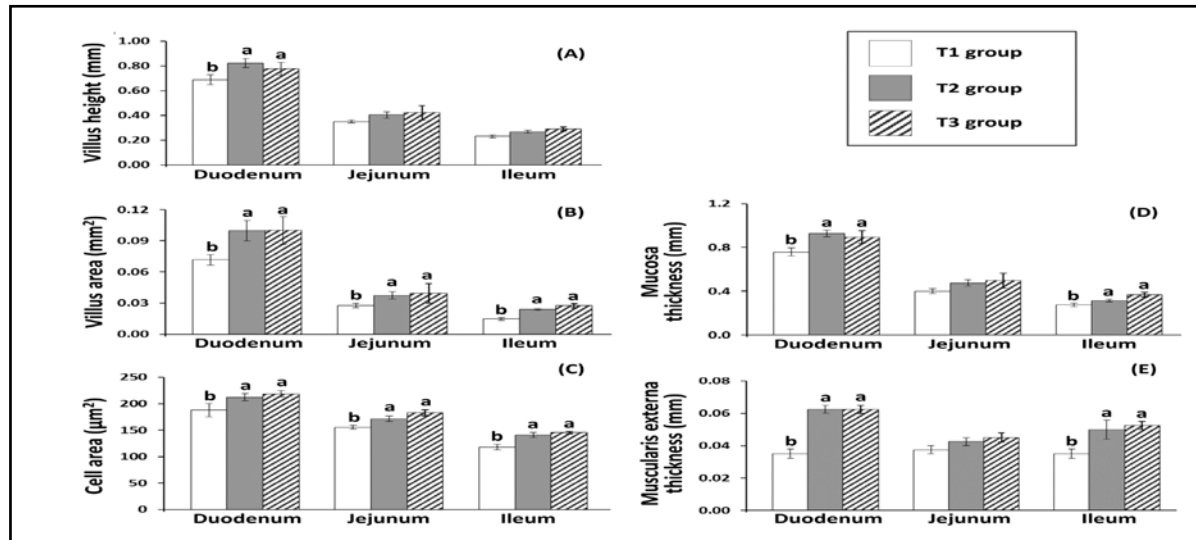
Regarding weight of pancreas, no significant ( $P > 0.05$ ) difference appeared in the group T2 ( $0.44 \pm 0.02^a$ ) and T3 ( $0.44 \pm 0.02^a$ ), whereas group T1 ( $0.32 \pm 0.00^b$ ) showed significant ( $P < 0.05$ ) difference compared to group T2 and T3. These results are in concomitant with (Bhanja *et al.*, 2009) who indicated that the feed intake significantly influences the GIT and visceral organs' development. Several other scientists also reported similar kinds of findings and recommended that baby chicks following hatching need instant feed for assurance of appropriate growth of GIT and its affiliated organs (Incharoen *et al.*, 2010). In connection to our study, it has also been reported that the post hatch withdrawal of water and feed impairs weight of all digestive organs (Maiorka *et al.*, 2003). Table 2 further depicts no significant ( $P > 0.05$ ) difference in the group T3 ( $3.20 \pm 0.25^a$ ) and T2 ( $3.30 \pm 0.15^a$ ), whereas group T1 ( $2.28 \pm 0.05^b$ ) found statistically different ( $P < 0.05$ ) from group T2 and T3 for weight of jejunum. Concerning weight of ileum, no significant ( $P > 0.05$ ) difference was found in the group T3 ( $2.90 \pm 0.21^a$ ) and T2 ( $2.64 \pm 0.09^a$ ), while group T1 ( $1.98 \pm 0.14^b$ ) showed prominent ( $P < 0.05$ ) variation compared to birds in group T2 and T3. Regarding the duodenum length, significant ( $P < 0.05$ ) difference appeared in the group T2 ( $25.92 \pm 0.51^a$ ) followed by T3 ( $20.32 \pm 0.77^b$ ) and T1 ( $18.24 \pm 0.29^c$ ). Group T2 ( $41.44 \pm 0.82^a$ ) also showed significant ( $P < 0.05$ ) difference against length of jejunum, but the group T3 ( $36.30 \pm 0.95^b$ ) and T1 ( $34.00 \pm 1.41^b$ ) showed no significant ( $P > 0.05$ ) difference. Further, significant ( $P < 0.05$ ) difference appeared in the group T2 ( $40.22 \pm 0.93^a$ ), and no significant ( $P > 0.05$ ) difference in group T3 ( $33.24 \pm 0.17^b$ ) and T1 ( $31.44 \pm 1.02^b$ ) for the length of ileum. These results with (Jimenez-Moreno *et al.*, 2010), where authors reported that the variation in the diet causes structural change in duodenum and its concerning parts.

Results regarding the villus height (mm), villus area ( $\text{mm}^2$ ), cell area ( $\text{mm}^2$ ), mucosa thickness (mm) and muscularis externa thickness (mm) are presented in the Figure 1. Results indicate significant ( $P < 0.05$ ) difference in the group T1 against villus height of duodenum, while group T2 and T3 showed no significant ( $P > 0.05$ ) difference compared to group T1. Regarding the villus height of jejunum and ileum no significant ( $P > 0.05$ ) difference appeared in group T1; however, change was significant ( $P < 0.05$ ) for area of villus, ileum jejunum and duodenum. Regarding cell area, group T2 and T3 showed no significant ( $P > 0.05$ ) difference, however T1 varied considerably ( $P < 0.05$ ). Figure 1 further shows no prominent ( $P > 0.05$ ) change in the group T2 and T3 against mucosa thickness of duodenum and ileum, whereas variation was significant ( $P < 0.05$ ) in the group T1. Concerning mucosa thickness of jejunum, although all the

means showed slight variation, statistically they were not different ( $P > 0.05$ ) from each other. Comparatively, significant difference ( $P < 0.05$ ) was seen in the group T1 and no significant difference among groups T2 and T3 against muscularis externa thickness of duodenum and ileum. Against muscularis externa thickness of jejunum, statistically no difference ( $P > 0.05$ ) was found among all the groups.

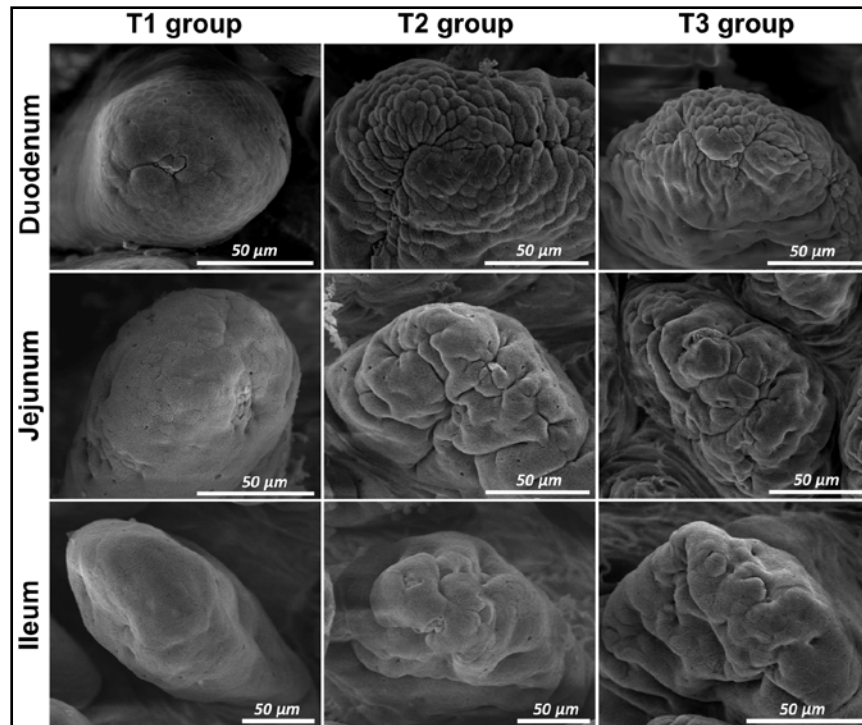
Our findings possess similarity with results of (Tabedian *et al.*, 2010) who stated that the height of villi in

jejunum and duodenum diminishes considerably ( $P < 0.05$ ) with the increase of feed withdrawal period. It is also supportive that feed deprivation of 5 - 6 days prominently ( $P < 0.05$ ) reduces the number of enterocytes and villi height (Yamauchi *et al.*, 2010). Further, morphological alterations in the villi of broilers are reliant on digested nutrients in the intestinal lumen (Panda *et al.*, 210). Cellular alterations in the apical surface of villi were observed under the electron microscope and observations are displayed in the Figure 2.



<sup>a-b</sup>Means with different letter designations are significantly different ( $P < 0.05$ )

**Figure 1.** Villus height (A), villus area (B), cell area (C), mucosa thickness (D) and muscularis externa thickness (E) in the duodenum, jejunum and ileum of chicks subjected to fasting and feed particle size variation.



Scale bar = 50 μm, magnification: ×1000

**Figure 2.** Scanning electron microscopic observations of apical surface of duodenum, jejunum and ileum in broiler chicks subjected to fasting and feed particle size variation.

Duodenal cellular morphology of chicks among different groups showed great variability in the appearance. Surface of villi was made up of only layer of epithelial cells in the group T1, while villi in group T2 followed by T3 possessed copious cell groups accumulated by several protruded epithelial layers surrounding sulcus centrale. Regarding cellular morphology of jejunum and ileum, copious bunches of cells were grouped and many epithelia surrounding the central sulcus were seen in the group T3. However, in group T1, villus apical surface was composed of many single epithelial cells only (Figure 2).

### 3.2. Growth performance

Results regarding different growth parameters are shown in the Table 3. Table indicates significant ( $P < 0.05$ ) difference in the group T2 ( $432.2 \pm 3.0^a$ ), while among groups T3 ( $403.3 \pm 6.7^b$ ) and T1 ( $399.7 \pm 4.8^b$ ) no significant ( $P > 0.05$ ) variation was observed for initial body weight. Weight gain significantly ( $P < 0.05$ ) differed in the group T2 ( $391.5 \pm 2.9^a$ ), but among groups T3 ( $363.7 \pm 7.1^b$ ) and T1 ( $360.2 \pm 5.1^b$ ) change was non-significant ( $P > 0.05$ ). Reported results of (Noy and Sklan, 1998) and (Hetland *et al.*, 2002) are also much similar to our study, when studying the newly hatched chicks in contrast to feeding practices. They showed 10.5 percent higher weight compared to chicks though they were fed following fasting of 2 days. It may be presumed that the late feeding of chicks may cause few stimulations in their GIT. Panda *et al.* (2010) have also reported supportive findings. According to their results, chicks (though accessed feed after fasting of two days) attained considerably lesser weight compared to that of those were early fed. Adverse effects of fasting of two days on chicks' development have also been stated by Juul-madsen *et al.* (2004). It was reported that fasting one day is adequate for appropriate performance of birds.

Table 3 further shows that no significant ( $P > 0.05$ ) difference was found in the group T2 ( $594.8 \pm 7.5^a$ ) and T1 ( $566.7 \pm 11.4^a$ ), while group T3 ( $511.7 \pm 18.3^b$ ) was statistically ( $P < 0.05$ ) different from the group T1 and T2 against feed intake. As for feed efficiency, group T3 ( $0.73 \pm 0.03$ ) showed higher mean value followed by T2 ( $0.69 \pm 0.02$ ) and T1 ( $0.67 \pm 0.02$ ) but statistically no significant ( $P > 0.05$ ) difference was found among all groups. Similar kinds of results have also been reported by other scientists like Mohiti-Asli *et al.* (2012) and Sklan *et al.* (2003), who revealed that fasting of short duration (0.5 day) positively influences the performance of broilers. In another study, it was found that the GIT performance of broilers is stimulated by proper concentration of dietary fiber fed from day 1<sup>st</sup> to 28<sup>th</sup> (Gonzalez-Alvarado *et al.*, 2008). It has also been reported that hulls derived from oat increase the retention of nutrients in the GIT because of higher level of insoluble fiber. Further, gizzard activity and overall digestibility are also enhanced during starter period that results in increased growth performance (Hetland and Svihus, 2001).

## 4. Conclusion

Current study concludes that post hatch fasting significantly affects the utilization of yolk sac, feed intake, gross and histological structures of digestive organs. Fasting for first few hours of hatching does not negatively

influence the birds, but fasting of 48 hours adversely impairs the performance, gross and histological structures of intestine and its affiliated organs as reported in the findings of current study. Thus, fasting of chicks for longer periods should be avoided.

## References

- Batal AB and Parsons C M. 2002. Effect of fasting versus feeding oasis after hatching on nutrient utilization in chicks. *Poult Sci.* **81**: 853-859.
- Bhanja S K, Devi C A, Panda A K and Sunder G S. 2009. Effect of post hatch feed deprivation on yolk-sac utilization and performance of young broiler chickens. *Asian-Aust J Anim Sci.* **22**: 1174-1179.
- Boersma S I, Robinson F E, Renema R A and Fassenko G M. 2003. Administering oasis hatching supplement prior to chick placement increases initial growth with no effect on body weight uniformity of female broiler breeders after three weeks of age. *J Appl Poult Res.* **12** (4): 428-34.
- Franco J R G, Murakami AE, Natali M R M, Garcia E R M and Furlan A C. 2006. Influence of delayed placement and dietary lysine levels on small intestine morphometrics and performance of broilers. *Braz J Poult Sci.* **8**: 233-241.
- Friedman A, Bar S E and Sklan D. 2003. Ontogeny of gut associated immune competence in the chick. *World's Poult Sci J.* **59**: 209-219.
- Geyra A, Uni Z and Sklan D. 2001. Enterocyte dynamics and mucosal development in the Post hatch chick. *Poult Sci.* **80**: 776-82.
- Gonzalez-Alvarado J M, Jimenez-Moreno E, Valencia D G, Lazaro R and Mateos G G. 2008. Effects of fiber source and heat processing of the cereal on the development and pH of the gastrointestinal tract of broilers fed diets based on corn or rice. *Poult Sci.* **87**: 1779-1795.
- Hassouna E M A. 2001. Some anatomical and morphometrical studies on the intestinal tract of chicken, duck, goose, turkey, pigeon, dove, quail, sparrow, heron, jackdaw, hoopoe, kestrel and owl. *Ass Vet Med J.* **44**: 47-78.
- Henderson S N, Vicente J L, Pixely C M, Hargis B M and Tellez G. 2008. Effect of an early nutritional supplement on broiler performance. *Int J Poult Sci.* **7**: 211-214.
- Hetland H and Svihus B. 2001. Effect of oat hulls on performance, gut capacity and feed passage time in broiler chickens. *Brit Poult Sci.* **42**: 354-361.
- [11] Hetland H, Svihus B and Olaisen V. 2002. Effect of feeding whole cereals on performance, starch digestibility and duodenal particle size distribution in broiler chickens. *Brit Poult Sci.* **43** (3): 416-423.
- Huang D S, Li D F, Xing J J, Ma Y X and Li Z J. 2006. Effects of feed particle size and feed form on survival of Salmonella Typhimurium in the alimentary tract and Salmonella Typhimurium reduction in growing broilers. *Poult Sci.* **85**: 831-836.
- Incharoen T and Maneechote P. 2013. The effects of dietary whole rice hull as insoluble fiber on the flock uniformity of pullets and on the egg performance and intestinal mucosa of laying hens. *Am J Agri Bio Sci.* **8**: 323-329.
- Incharoen T, Yamauchi K and Thongwittaya N. 2010. Intestinal villus histological alterations in broilers fed dietary dried fermented ginger. *J Anim Phys & Anim Nutr.* **94**: 130-137.
- Jia W and Slominski B A. 2010. Means to improve the nutritive value of flaxseed for broiler chickens: The effect of particle size, enzyme addition, and pelleting. *Poult Sci.* **89**: 261-269.

- Jimenez-Moreno E, Chamorro S, Frikha M, Safaa H M and Lazaro R. 2011. Effects of increasing levels of pea hulls in the diet on productive performance, development of the gastrointestinal tract and nutrient retention of broilers from one to eighteen days of age. *Anim F Sci Tech*. **168**: 100-112.
- Juul-Madsen H R, Su G and Sørensen P. 2004. Influence of early or late start of first feeding on growth and immune phenotype of broilers. *Br Poult Sci*. **45**: 210-222.
- Khambualai O, Ruttanavut J, Kitabatake M, Goto H and Erikawa T. 2009. Effects of dietary natural zeolite including plant extract on growth performance and intestinal histology in Aigamo ducks. *Brit Poult Sci*. **50**: 123-130.
- Krás R V, Kessler A M, Ribeiro A M L, Henn J D and Bockor L. 2013. Effect of dietary fibre, genetic strain and age on the digestive metabolism of broiler chickens. *Braz J Poult Sci*. **15**: 83-90.
- Maiorka A, Santin E, Dahlke F, Boleli I and Furlan R. 2003. Post hatching water and feed deprivation affect the gastrointestinal tract and intestinal mucosa development of broiler chicks. *J Appl Poult Res*. **12**: 483-492.
- Mateos G G, Jimenez-Moreno E, Serrano M P and Lazaro R P. 2012. Poultry response to high levels of dietary fiber sources varying in physical and chemical characteristics. *J Appl Poult Res.*, **21**: 156-174.
- Mohiti-Asli M, Shivazad M, Zaghari M, Rezaian M and Aminzadeh S. 2012. Effects of feeding regimen, fiber inclusion and crude protein content of the diet on performance and egg quality and hatchability of eggs of broiler breeder hens. *Poult Sci*. **91**: 3097-3106.
- Noy Y and Sklan D. 1998. Yolk utilization in the newly hatched poult. *Br Poult Sci*. **39**: 446-451.
- Panda A K, Raju M V L N, Rama R S V, Shyam S G, Reddy M R. 2010. Effect of post-hatch feed deprivation on growth, immune organ development and immune competence in broiler chickens. *Anim Nutr F Tech*. **10**: 9-17.
- Peron A, Bastianelli D, Oury F X, Gomez J and Carre B. 2005. Effects of food deprivation and particle size of ground wheat on digestibility of food components in broilers fed on a pelleted diet. *Br Poult Sci*. **46**: 223-230.
- Pourreza J, Zamani F, Tabeidian A A and Toghyani M. 2012. Effect of early feeding or feed deprivation on growth performance of broiler chicks. *Res Op Anim & Vet Sci*. **2**: 136-140.
- Rougière N, Gomez J, Mignon-Grasteau S and Carré B. 2009. Effects of diet particle size on digestive parameters in D+ and D-genetic chicken lines selected for divergent digestion efficiency. *Poult Sci*. **88**: 1206-1215.
- Silva A V, Majorka A, Borges S A, Santin E and Boleli I C. 2007. Surface area of the tip of the enterocytes in small intestine mucosa of broilers submitted to early feed restriction and supplemented with glutamine. *Int J Poult Sci*. **6**: 31-35.
- Sklan D, Smirnov A and Plavnik I. 2003. The effect of dietary fibre on the small intestines and apparent digestion in the turkey. *Br Poult Sci*. **44**: 735-740.
- Svihus B, Sacranie A, Denstadli V and Choct M. 2010. Nutrient utilization and functionality of the anterior digestive tract caused by intermittent feeding and inclusion of whole wheat in diets for broiler chickens. *Poult Sci*. **89**: 2617-2625.
- Tabedian S A, Samie A, Pourreza J and Sadeghi G H. 2010. Effect of fasting or post-hatch diet's type on chick development. *J Anim & Vet Adv*. **9 (2)**: 406-413.
- Wang J X and Peng K M. 2008. Developmental morphology of the small intestine of African ostrich chicks. *Poult Sci*. **87**: 2629-2635.
- Yamauchi K, Incharoen T and Yamauchi K. 2010. The Relationship between intestinal histology and function as shown by compensatory enlargement of remnant villi after midgut resection in chickens. *The Anat Rec Adv Integ Anat & Ev Bio*. **293 (12)**: 2071-2079.